

Inside a Laboratory that Looks Inside Horses' Hooves

by Lisa Simons Lancaster MSc PhD



Robert Bowker VMD PhD Director of the Equine Foot Laboratory at Michigan State University College of Veterinary Medicine.

AT MICHIGAN STATE UNIVERSITY'S EQUINE FOOT LABORATORY, veterinary researcher Robert Bowker VMD PhD and his staff of student investigators are working on unanswered questions about the horse's hoof. Over the past ten years, with funding support from the American Quarter Horse Association and the Grayson Jockey Club Equine Research Fund, Bowker has studied adaptive mechanisms in horse feet.

Hoofcare & Lameness readers may be familiar with Dr. Bowker's earlier work, published in this journal, documenting the existence of touch and position receptors in the frog and details of innervation in the navicular area. More recent research reveals that navicular syndrome is not limited only to pathology of the navicular bone but also involves bone density changes in the distal phalanx. Current research in MSU's equine foot lab is investigating changes in morphology (study of form and structure) and density of the epidermal laminae in differently shaped feet, with continued funding from AQHA and GJCERF.

Histology is the microscopic examination of cells and tissues. Early histological studies of the horse's hoof were done in the 1940s by the Swedish researcher Obel, who studied microscopic changes during acute bouts of laminitis. From Doug Leach's

pioneering research in 1980, we now know some basic facts about hoof growth and Chris Pollitt's Australian research confirms and expands Leach's findings about growth of the outer hoof wall.

At MSU, research on hoof growth continues by focusing on the inner hoof wall and its adaptive capacities, using histology to study laminae, hoof wall, digital cushion, lateral cartilage, frog, and bone.

Dr. Bowker's work, combined with studies from other investigators, is charting the adaptive mechanisms of the equine foot. Bowker asks questions such as: How does the foot function and grow? And how do healthy feet differ from unhealthy feet? Through a study of anatomy, physiology and histology, Bowker and his students

Quarter horse feet arrive in Michigan ready to be studied.



are finding some answers to these questions.

To date, findings reveal various means by which the foot responds to changing forces. Bowker is documenting adaptive changes in the morphology, physiology, and biochemistry of the inner foot.

Textbooks have mentioned that the digital cushion and hoof wall are the primary mechanisms to dissipate energy. Yet until Bowker's 1998 publication of the hemodynamic flow hypothesis, there had been no systematic documentation of how the inner tissues of the caudal hoof might accomplish this vascular-based energy dissipation.

Bowker's study of digital cushion and lateral cartilages in different breeds and ages revealed another new finding: the inner hoof structures have varying compositions across the horse population.

The metabolic rate of the horse's foot has not yet been scientifically determined, but based upon the structure and function of tissues within the foot the rate is probably low.

Bone's response to stress is a well-documented physiological adaptive process whereby bone is added or removed depending on the forces acting upon it. What was not documented until researchers at the MSU foot lab identified it was one specific way in which the navicular bone and P3 respond to different loads. In navicular syndrome, degenerative changes occur in the bone, digital cushion, and lateral cartilage. Cells and tissues respond to changed load by changing their biochemistry and subsequently the tissue architecture. Bowker found that the composition of the digital cushion and lateral cartilage varied between sound and lame horses.

Bowker's study of inner hoof morphology and tissue composition in navicular compared to sound horses yields intriguing new findings.

The information gathered from post-mortem feet has spurred many new research questions. People often ask if farriers and veterinarians can evaluate the digital cushion, lateral cartilage and coffin bone density? Are these changes a result of navicular disease or a cause of it? What environmental factors played a role in the affected versus control horses lives that may account for any of these changes? How much of this inner structure health is genetically determined? Can trimming and shoeing affect the inner structures in as obvious a way as they can affect the outer structures?

At this time, we do not have answers. There are currently no widely available imaging or biopsy techniques available to do such a study on live horses.

However Magnetic Resonance Imaging (MRI)

at Washington State University Veterinary Teaching Hospital has been successfully used to study navicular disease and may become more available in the future.

Relating External Markers to Internal Hoof Health

Laminitis research over the years has established that toe wall and white line distortion can indicate something about the integrity of the laminar bond. Dave Duckett's studies have shown the relationship between certain external markers and the location of internal structures. Bowker found a clear difference in the composition and integrity of inner hoof structures between navicular and non-navicular feet, so we wonder how this relates to outer hoof form.

It seems intuitively plausible that something like frog atrophy could be an indicator of digital cushion health. Or that hoof wall thickness or distortions in the quarters could be indicative of the lateral cartilage structure. But we simply do not know at this time.

Farriers define healthy feet as balanced with good horn quality and no distortion. We can assume that such feet have good inner structures. But we might be wrong!

Perhaps it is these good inner structures that explain some of the tough horses out there—the ones that never go lame despite neglect or abuse. Maybe good balance can make up for lack of good inner structure, or perhaps inner and outer balance really are correlated.

Studies are underway to find answers to these and other hoof related questions.

Lisa Lancaster dons a gas mask to check a group of feet from racing Quarter horses.

Partial funding for these and other of Lisa Lancaster's research projects is provided by Smoke Rise Farm in South Woodstock, Vermont. Photos and art for this article were supplied by Lisa Simons Lancaster, Dr. Robert Bowker, and the Michigan State University Equine Foot Laboratory. Special thanks to Mr. Ransome Sloan.

The metabolic rate of the horse's foot has not yet been scientifically determined, but based upon the structure and function of tissues within the foot, the rate is probably low.



The Farrier in the Laboratory

AS A VET STUDENT AND researcher now working in Dr. Bowker's equine foot lab, I have temporarily left my former world of live horses and the hard physical work using nippers and rasps. My work now consists primarily of dead feet, the smell of formalin, and the demanding mental course work of the veterinary medicine curriculum. During the school year my time with live horses is limited, but in the summer I work as a farrier while still doing some lab work.

I came to MSU with some understanding about the outside of the foot, but very little about the

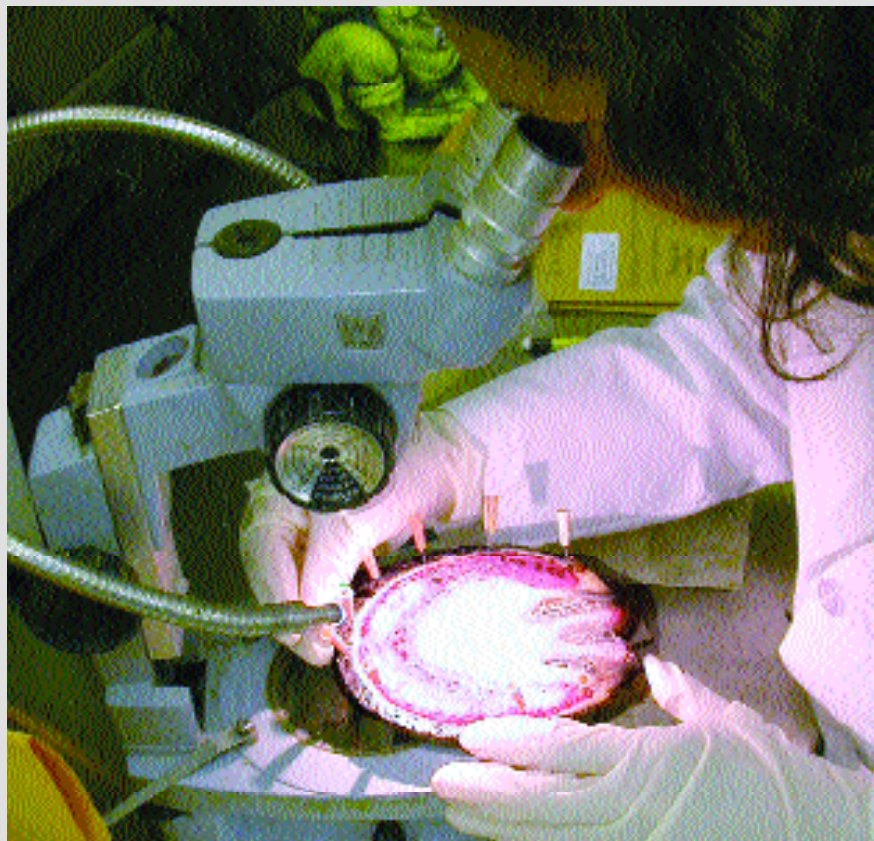inside. In shoeing school I had studied the textbooks by Butler, read chapters on the hoof in veterinary texts such as Adams' Lameness in Horses, and marveled at Chris Pollitt's Color Atlas of the Horse's Foot. I had been to continuing education events, inspected Allie Hayes' freeze-dried specimens, and watched Dave Duckett dissect a hoof. I learned something from each experience. But still I had not been able to really visualize the hoof in three dimensions or understand how the microanatomy constructed the wall, sole, frog, digital cushion, and lateral cartilages. After

two years of working in the foot lab, looking under the microscope, and studying hoof specimens cut every which way, I am developing an appreciation of how the foot is put together.

Now when I work on living horses, I have in mind images of what those parts look like on the inside. As I rasp off flares, shorten toes, use my knife on retained sole, or change the base of support, I visualize inner structures. Almost automatically, I find myself conducting a laboratory protocol check:

- What are the tubules doing?
- Does this affect blood flow?
- What do the cells of tubular horn look like at different levels in the foot?
- What is going on in the laminae and inner hoof wall when the white line is stretched?
- If the horse appears to do well after my trimming or shoeing, is this because of what I have done or despite it?
- Will the horse continue to benefit in the long run or is this apparent success deceptive?

Before working in the foot lab, my experience of looking down a



Lisa Simons Lancaster
examining a hoof "slice"
under the microscope.

microscope was limited to freshman college biology. Like all farriers, I had heard the terms "primary and secondary laminae", "dermal-epidermal junction", and "lamellar wedge". It's one thing to hear the terms or look at beautifully-colored diagrams in Chris Pollitt's books; it's quite another to identify them in unmarked histological slides with a professor standing at your side saying, "See, there it is, do you get it now?!?"

When students first learn histology, it is difficult for them to understand the orientation of the tiny piece of tissue on the slide in relation to the larger organ from which it came. I would have to ask Dr. Bowker which side of the slide was sole, which was wall (they do look similar!) and he'd sigh, wondering, I'm sure, just how long it would take me to figure this out. Slowly, with the persistent help of everyone at the lab, I am learning the 3-D construction of the microanatomy of the foot.

Even on the macroscopic tasks, like pulling shoes off dead feet, I was not particularly adept. Racehorse feet are cut off below the fetlock, leaving nothing to hang on to, and they are slippery! Pulling shoes off them reminded me of the first week of shoeing school. Dr. Bowker watched me struggle with it and his wry

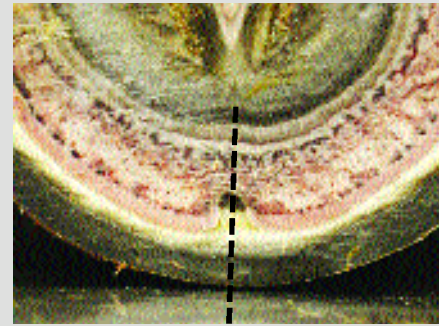
comment was simply, "And you call yourself a farrier..."

Although there is no widespread agreement on exactly how to trim and shoe feet to maximize hoof strength, farriers would concur that there are general indicators of healthy feet. It is not yet known exactly how these morphological markers correlate with internal structures..

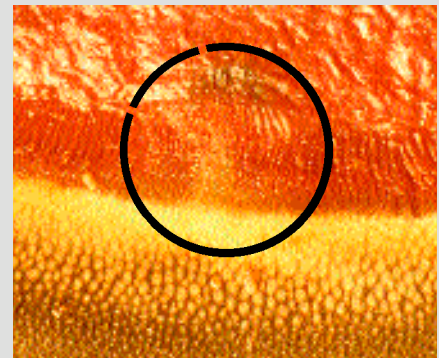
While I prefer the smell of horse manure to that of dead feet, and working under live horses may be more immediately satisfying to me than doing the hard work of research, I would not want to give up the privileged vantage point of the lab. I am honored to have Dr. Bowker as my mentor, to see the horse's foot from the inside, to learn histology, and to fuse all this knowledge with what I continue to learn as a farrier.

I look forward to the day when I again work on feet full time, but for now, I exchange my farrier's apron for a white lab coat for part of the year. I am fortunate to be part of Bowker's team at the MSU foot lab, and hope that my work will contribute to the efforts of other farriers and researchers who are building an inner terrain map of the equine hoof.

—Lisa Simons Lancaster



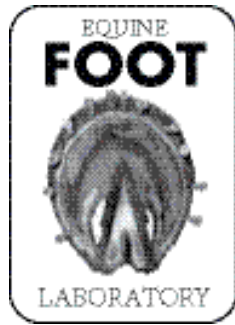
The crena or "center notch" of P-3 has characteristics that vary both between horses and bones. Here, the notch of horn in the laminar junction shows a dark pigmented area to the inside of the dermal laminae, significance unknown.



A different foot sliced at same level above sole plane as image above. The area circled at mid-toe shows no horn notch, but there is a shape change in the laminar junction and a small dark spot to the inside of the dermal laminae. Both feet looked the same on the solar surface: farrier's view showed the familiar round hole in the white line at mid-toe.



Researcher Sue Spaulding slices coffin bones through the crena to collect data.



Density of Hoof Wall Tubules:

Is the construction of the hoof wall the same in all horses?

One project underway in our lab is a study of hoof wall tubular density. Previous studies by British researcher J.D. Reilly have documented a zonal pattern of tubule density.

Reilly found that the tubules are larger and further apart from each other in the inner hoof wall and are increasingly smaller and more tightly packed together in the outer hoof wall. The tubules become progressively more cornified (hardened) and more closely spaced as the living cells die. The end result of this process is the small, hard tubules at the very outer edge of the hoof wall that farriers can rasp, nail, or heat without causing any pain sensations to the horse.

Reilly looked at a cross section from the dorsal toe wall at the midpoint between hairline and ground.

German researcher KD Budras has also studied hoof horn tubules. Budras has found intriguing differences between wild and domestic horses' hoof tubules. (See Hoofcare & Lameness issues #70 Budras, KD: "White Line Comparison" and #74 Budras, KD: "German research examines hoof-repair materials").

We are building on this past work to investigate the following questions:

Does tubule density change over time or are horses born with one pre-determined tubule pattern and density? Is tubule density in QH racehorse feet the same as the slaughterhouse horses used in Reilly's study? Does the tubule density vary around the perimeter of the hoof or is the variation found between inner and outer horn density the same in the toe, quarter and heel? If there turns out to be variation around the perimeter, does this correlate with the laminar density variation found in our other studies? Does tubular density or tubular morphology correlate with any other internal structures, such as bone or cartilage fiber alignment? Does tubule density correlate with hoof shape such as flares, dishes, or cracks?

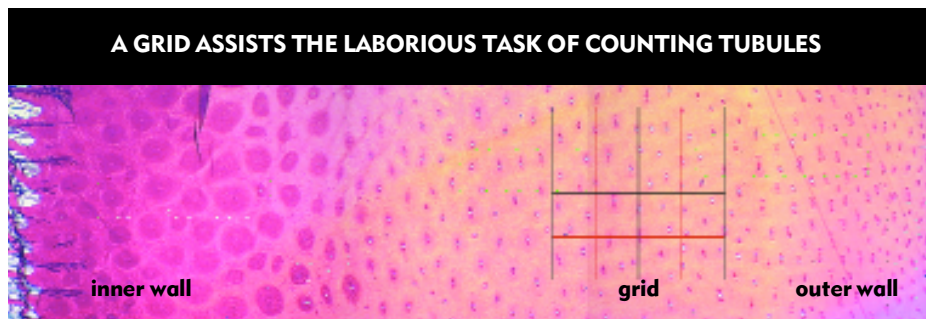
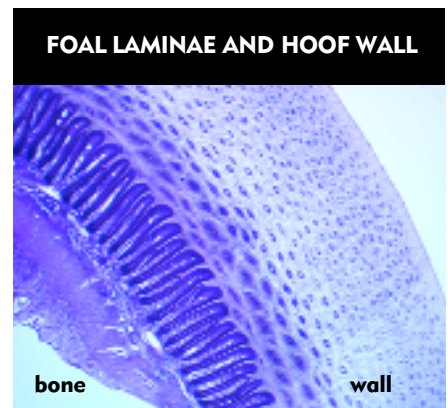
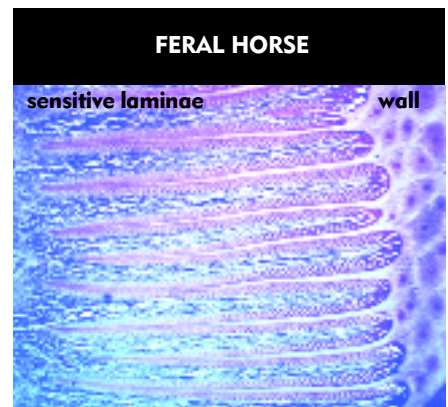
HISTOLOGY IMAGES

These are cross sections taken from the dorsal toe wall. There is no clear demarcation between inner and outer hoof wall but you can see the general pattern of tubules getting smaller towards the outer edge.

TOP: Laminae and inner hoof wall from a feral horse.

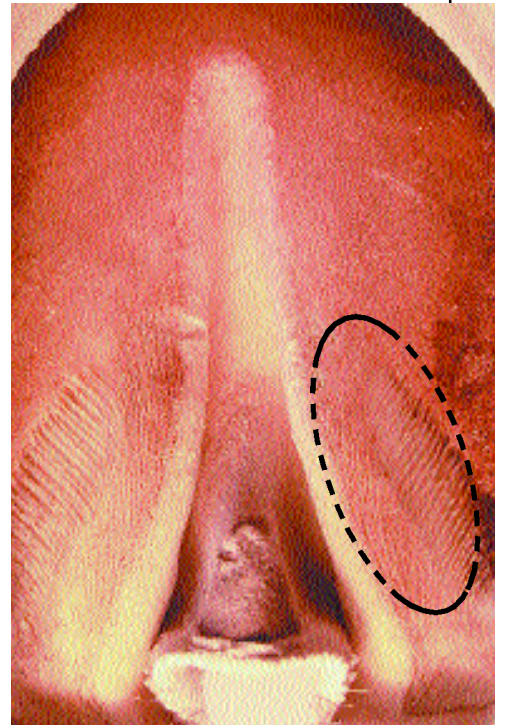
MIDDLE: Laminae and full thickness hoof wall from a foal.

BOTTOM: Outer edge of laminae and full thickness of hoof wall from a QH racehorse. (In all three images, the outer wall is on the right.)



Recognizing deformity or malfunction in the bars may turn out to be an important first step in restoring symmetry and function.

We have always assumed that the structure of the bars is virtually identical to the hoof wall at the toe and quarters, because both have primary and secondary epidermal laminae. The bars are generally thought to be an actual continuation of the hoof wall with laminae reaching into the sole at an angle dictated by the bars' shape, which in turn is one of several external parameters used by farriers to judge how strong and well-formed a foot is. Collapsed bars indicate weakness in the back of the foot. However, recent research by Robert Bowker VMD PhD shows that the bars have a more complex structure, including what he has termed tertiary (three level) epidermal laminae (TEL). On a microscopic level at least, the bars' laminae (in circle at left) appear able to form tubular horn and contribute cells to the growth of both the hoof wall and the sole. The orientation of these new sole's tubules is influenced by the position of the bars and may be dependent on pressure during stance. Recognizing deformity or malfunction in the bars may turn out to be an important first step in restoring symmetry and function.



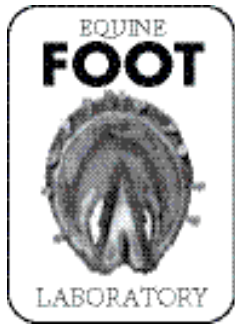
How does the shape of the bars influence sole growth and hoof shape? How important are newly discovered sole-growth TEL mechanisms in the tips of the laminae of the bars (circle) to the shape of the foot and thickness of sole?

How do nail holes affect the hoof wall above the white line?

Since many of the feet studied at Michigan State are from racing Quarter horses, the feet are relatively young and the nails used in their shoes are light race nails used to hold on light aluminum race plates. In the "slices" of hoof specimen above the white line, nail holes are visible where they passed through the wall en route to an exit and a clinch. This highly magnified image taken through a microscope shows the clear route a nail took through the wall, with a darkening of tubules on the inside of the nail hole that has not, as yet, been studied or compared with "slices" from older horses.



Nail holes pass through the hoof wall above the white line on their way to an exit and a clinch.



500 Laminae and Counting

Lisa Lancaster outlines the anatomy of a study on wall flares and laminar density

The laminar density study made use of the feet of dead racing Quarter horses which had good foot mass. (Note "slicing" pattern for vertical sections.) Shaded drawings below indicate variations in laminar density of the white line based on age and hoof capsule distortion. Diagonal flares with underrun heels resulted in an unusual density pattern (far right, bottom).

Biomechanics studies using force plates, strain gauges, and pressure transducers have documented mechanical stress to the hoof during movement and stance, but very little is known about the mechanisms involved in the foot's response to these documented forces. In this study, we focus on the laminar junction as one area that responds to stress, and density variation as one mechanism

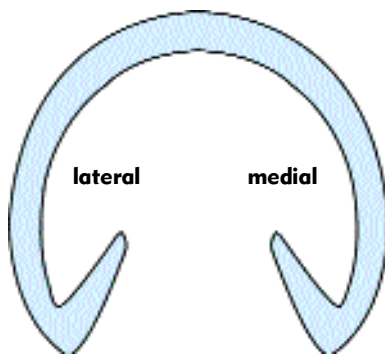
of the foot's adaptive capacity.

Laminar density appears to be one important adaptive mechanism of the horse's hoof. The number and spacing of laminae is not fixed throughout the life of the horse.

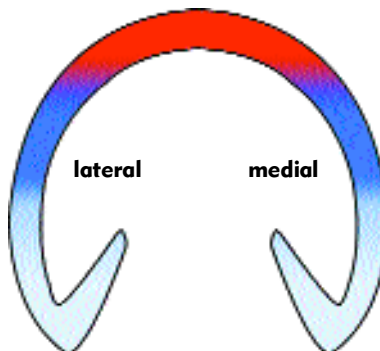
In newborn foals, the spacing of the laminae is more consistent around the whole perimeter. In adult feet, laminar density is lower at the quarters and higher at the toe.

There is evidence that shorter-toed and square-toed feet have different laminar density and morphology than long-toed feet. In wild horse feet, histology reveals laminae that look more like a foal's feet in terms of spacing and morphology.

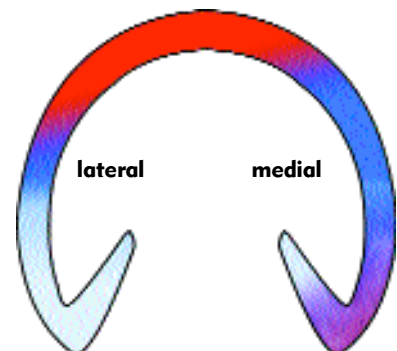
Farriers see evidence of fast changes in the hoof wall when flares are removed and thin-walled quarters get thicker. What is happening in the distal hoof wall when weak walls respond to different trimming or shoeing methods and get thicker in a matter of weeks? Bowker's findings of adaptive capacities in the inner hoof wall might explain the changes. It is possible that laminae in the distal hoof wall are capable of adding horn tubules as needed when load is manipulated after the farrier changes the weightbearing surface.



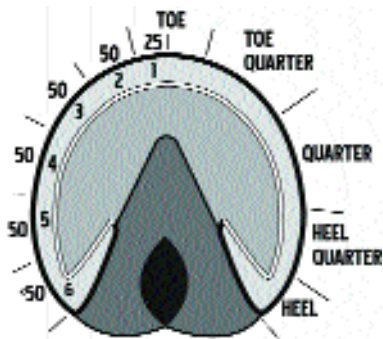
A newborn foal's foot: uniform laminar density of entire circumference of the hoof wall.



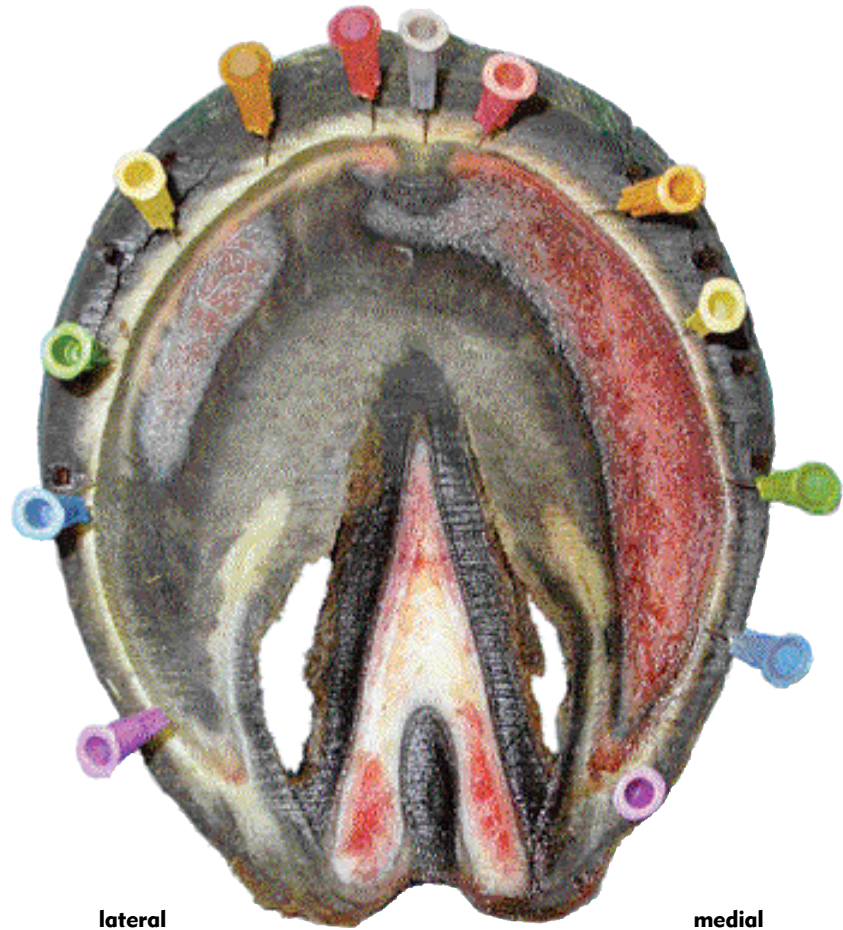Adult symmetrical foot: uniform variation in laminar density; highest density at toe, lowest density at heels.



Adult asymmetric foot (left front): density pattern disrupted; underrun medial heel and diagonal flare at toe quarter.



Hoof map of normal laminae



lateral

medial

The road from slices of hoof to an analysis of laminar density required the creation of a “hoof mapping” system that would both facilitate counting laminae in distinct regions of the foot, and also create landmarks for consistency among individual hooves in the study.

Pins in the hoof wall of slice samples acted as guides for researchers assigned to count the laminae in medial and lateral portions of the hooves.

A pin is placed in the center of the toe. On either side of that pin, the researcher counted 25 laminae, then planted a pin at that point, and labeled this a “zone” of the white line of that foot. For each of the other zones of the

foot, the researcher counted 50 laminae, and placed another pin.

The drawing (above left) illustrates the scheme; numbers on the outside indicate the number of laminae to be counted before placing another pin. Labels on the right are common farrier terms for sections of the foot.

Compare the normal drawing with the “mapping” of a solar slice (large photo) taken from the level of the sole plane.

Obviously, the pins on the lateral side (left in photo) are closer together than on the medial side, indicating that the laminae are more dense on the lateral side. In other words, on the flared side of the foot (lateral side in

this example) the laminae are closer together than they are on the more medial, or non-flared side of the of foot.

Additionally, in the opposite diagonal (medial) heel, the pins are closer together than on the lateral side, possibly an effect of the underrun heel.

These findings suggest that the epidermal laminae are not evenly distributed around the hoof wall but that they may be distributed according to variations in loads and stresses applied to the hoof wall. Such potential differences in laminar distribution suggest the importance of maintaining a balanced foot and the critical role of hoof trimming and farrier perception of hoof balance.

Sole Plane Excavation in the Field

As part of my job at the lab, I study what is currently known about the histology of the horse's hoof. —Based on this knowledge, I am developing new lines of investigation to be used on live horses.

Modifying the lab techniques developed for cadaver feet, I am testing ways to collect and record information from living horses' feet so that we can track changes over time in some of the variables that have been identified in the lab.

Some farriers track their client's horses by recording hoof measurements such as lengths and angles, and photographing the feet at regular intervals. Radiographs are another tracking tool to follow changes and to correlate inner and outer hoof form.

I have been keeping detailed records on my client's horses for years. I now have a way to add some internal variables to these records. At the foot lab we are developing techniques for histology on samples from live horses.

To determine laminar density, any cross-section of the hoof can be used. But below P3, the laminar junction becomes the white line, attaching wall to sole. The number of primary epidermal laminae remains the same but the tissue architecture of the white line is slightly different from that of the laminar junction at the level of the distal phalanx. The white line connects the unexfoliated wall to the sole. This is the level of the sole plane.

Gene Ovnicek teaches farriers that the sole plane is the junction between live and exfoliating sole, and this is a useful reference for the level to which the sole should be trimmed.

On some feet this zone between exfoliating and live sole is easy to find. On other feet it can be a challenge to identify the real live sole from sometimes look-alike retained sole. Experienced farriers can usually tell the difference.

But what is it about some feet that generate more retained sole than other feet? Does false sole differ histologically from the true live sole? At the foot lab we are looking into these and other questions about the sole plane, the white line, and morphological markers in these tissues over time in differently shaped feet.

One of the few areas of agreement in the realm of hoof function is that the hoof adapts to its environment.

Farriers and horsemen are familiar with the changing external appearance of the hoof which depends on factors such as trimming and shoeing, ground surface, workload, and nutrition.

What is less obvious is how the hoof accomplishes these adaptive changes.

The answers will come from hooves tested in both the laboratory and the real world. The answers may surprise us all, if we can find the key to how the normal, healthy hoof works.

Questions beg to be asked:

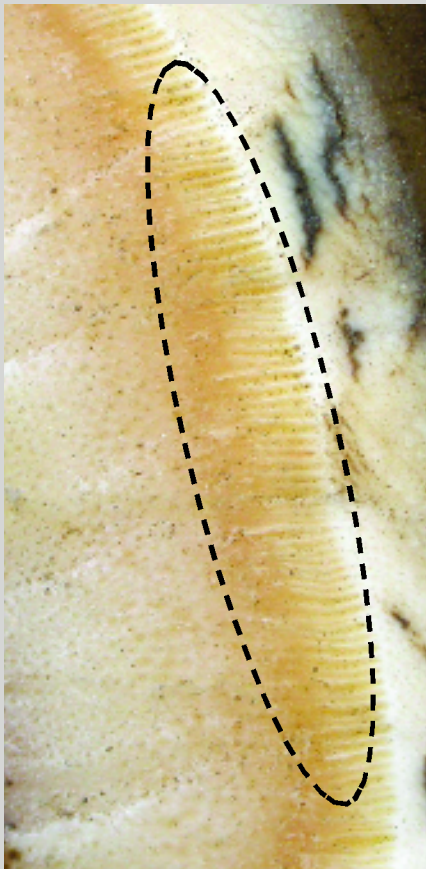
What exact biological and physical mechanisms are involved when a hoof changes form?

What happens inside the foot when external horn tubules lose their integrity?

How does the hoof dissipate energy of impact?

What are the internal structural differences that account for strong versus weak hooves?

How do changes made by farriers to the weightbearing surface influence inner structures to alter their form and function?



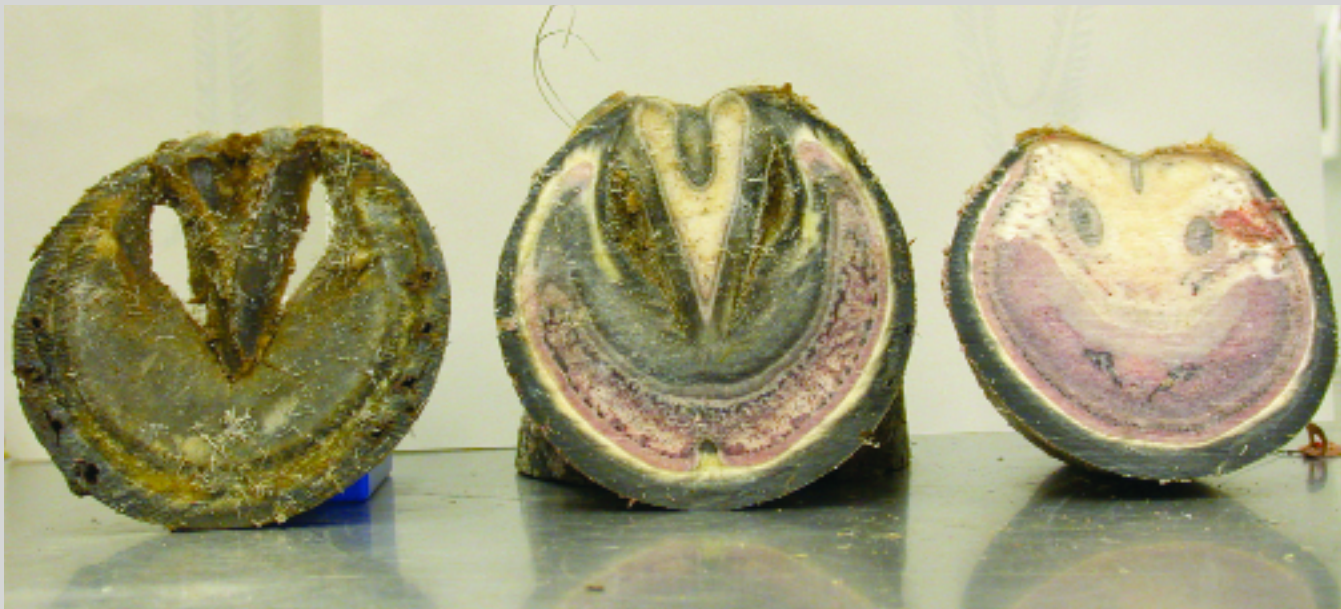
The laminae shows minute variations that may one day prove to have meaning to the horse's metabolic or athletic function.



Transferring laboratory findings to real horses will require sample collection. Lisa often collects hoof samples from horses she works on during breaks from school and lab work. This horse is an example of one with irregular forces on the hoof; the sample will have its laminae counted to see if the diagonal ratio holds true in normal living horses. Wall-sole junction samples are collected, labeled, and preserved in solution for transport to the laboratory.

TO LEARN MORE:

Check the Equine Foot Laboratory's web site: <http://www.cvm.msu.edu/RESEARCH/efl/index.htm> • Watch for the publication of Lisa Simons Lancaster's new book *The Sound Hoof: Horse Health From the Ground Up* late in 2004. • Read Dr Bowker's papers in the Proceedings of the 49th Annual AAEP Convention, available online to subscribers at www.ivis.org: "Contrasting Structural Morphologies of 'Good' and 'Bad' Footed Horses" and "The Growth and Adaptive Capabilities of the Hoof Wall and Sole: Functional Changes in Response to Stress".



Hoof sections from deceased racing Quarter horses are laboratory stand-ins for real-world horses.